

See discussions, stats, and author profiles for this publication at: <https://www.researchgate.net/publication/318396551>

# Transcoelomic expulsion of an ingested foreign object by a carcharhinid shark

Article in *Marine and Freshwater Research* · January 2017

DOI: 10.1071/MF17022

CITATIONS

7

READS

486

7 authors, including:



**Steven T Kessel**  
Shedd Aquarium

82 PUBLICATIONS 2,574 CITATIONS

[SEE PROFILE](#)



**Jill Louise Brooks**  
Carleton University

19 PUBLICATIONS 235 CITATIONS

[SEE PROFILE](#)



**Tristan L Guttridge**  
Saving the Blue

65 PUBLICATIONS 1,252 CITATIONS

[SEE PROFILE](#)



**Nigel E Hussey**  
University of Windsor ([www.husseylab.com](http://www.husseylab.com))

185 PUBLICATIONS 4,135 CITATIONS

[SEE PROFILE](#)

Some of the authors of this publication are also working on these related projects:



A review of deepwater telemetry [View project](#)



Habitat use and movement patterns of Arctic marine fishes [View project](#)

## Transcoelomic expulsion of an ingested foreign object by a carcharhinid shark

S. T. Kessel<sup>A,H</sup>, J. Fraser<sup>B</sup>, W. G. Van Bonn<sup>C</sup>, J. L. Brooks<sup>D</sup>, T. L. Guttridge<sup>E</sup>,  
N. E. Hussey<sup>F</sup> and S. H. Gruber<sup>G</sup>

<sup>A</sup>Daniel P. Haerther Center for Conservation and Research, John G. Shedd Aquarium,  
1200 South Lake Shore Drive, Chicago, IL 60605, USA.

<sup>B</sup>Ocean Artworks LLC, Boynton Beach, FL 33435, USA.

<sup>C</sup>A. Watson Armour III Center for Animal Health and Welfare, John G. Shedd Aquarium,  
1200 S Lake Shore Drive, Chicago, IL, 60605, USA.

<sup>D</sup>Fish Ecology and Conservation Physiology Laboratory, Department of Biology,  
Carleton University, Ottawa, ON, K1S 5B6, Canada.

<sup>E</sup>Bimini Biological Field Station Foundation, South Bimini, Bahamas.

<sup>F</sup>Biological Sciences, University of Windsor, 401 Sunset Avenue, Windsor, ON,  
N9B 3P4, Canada.

<sup>G</sup>Rosenstiel School of Marine and Atmospheric Sciences, University of Miami, Miami,  
FL 33149, USA.

<sup>H</sup>Corresponding author. Email: skessel80@gmail.com

**Abstract.** A wild lemon shark (*Negaprion brevirostris*) was observed to expel an ingested foreign object through its body wall, over a minimum period of 435 days. We observed this lemon shark at a recreational diving feeding site off the coast of Juno Beach (FL, USA) on 12 occasions between 6 December 2014 and 14 December 2016. At the final observation, following expulsion, we observed this lemon shark with scar tissue and in apparent healthy condition. At minimum, this lemon shark was able to survive for over 1 year under perforation of its stomach lining, coelom and body wall. This account provides further evidence for the resilience and recovery capabilities of elasmobranch fish.

**Additional keywords:** deep hook, diver observation, gut hook, lemon shark, stomach eversion, spiral valve eversion.

Received 27 January 2017, accepted 2 May 2017, published online 13 July 2017

### Introduction

Ingestion of foreign objects by sharks has long been established in both the literature and popular culture. This has largely been the result of a long-standing human fascination with cutting open shark stomachs to reveal strange contents, such as bibles, unexploded bombs and ticking watches (Gapps 2011). As far back as 1949, oil cans, tin cans, rope and a large piece of tile were documented in the stomach contents of tiger sharks (*Galeocerdo cuvier*) in the Florida Keys (Gudger 1949). Questions surround the motivation and cause of ingestion events, but arguably the more important issue is the implication of foreign objects in the stomachs of sharks relative to their health and post-ingestion survival.

Many shark species are capable of expelling objects through the voluntary induction of stomach eversions, a known mechanism to facilitate expulsion of indigestible matter from their stomachs (Brunnenschweiler *et al.* 2005). Famously, in 1935, a tiger shark housed in the Coogee Aquarium Baths (Sydney, NSW, Australia) ejected a human arm in this manner in front of unsuspecting patrons (Castles 1995). Multiple elasmobranch

species in captivity and in the wild have been documented to eject some small objects by the eversion and protrusion of their spiral valve through their cloaca to rinse it of debris (Christie 2012; Wiersma *et al.* 2016). However, if the ingested object is too big, or the shark is unable to disgorge it through these mechanisms, what is the expected fate for that individual?

A necropsy of a washed up whale shark (*Rhincodon typus*) in Thailand indicated the cause of death to be internal injuries as a result of the ingestion of a rigid plastic straw (Haetrakul *et al.* 2009). A juvenile sand tiger shark (*Carcharias taurus*) held in captivity at the Singapore Zoo ingested part of the exhibit rockwork. After failing to expel the object after 3 weeks, it was deemed necessary to surgically remove the item (Lloyd and Lloyd 2011). Under such circumstances, where sharks are unable to expel ingested foreign objects either through the digestive system or by stomach eversion, are there other methods that the animal may adopt to rid themselves of the item?

Herein, we document observations of a wild adult lemon shark (*Negaprion brevirostris*) that was able to expel an ingested

foreign object through its coelom and body wall over a minimum period of 435 days. Over this period, the foreign object was progressively expelled through the coelom and body wall until it was completely ejected, and the body wall healed to the point that the only lasting external evidence was scar tissue. To the best of our knowledge, this is the first documented account of transcoelomic expulsion of a foreign object by an elasmobranch.

### Materials and methods

A mature male lemon shark (~250-cm estimated total length) was observed on 12 occasions between 6 December 2014 and 14 December 2016 at a recreational diving shark feeding site known as the 'Lemon Drop', located off the coast of Juno Beach, Florida (20°53'N, 79°59'W). Occurrence at the feeding site was exclusively during the winter months of December–February each year, consistent with the seasonal presence of lemon sharks in this region (Kessel *et al.* 2014).

### Ethical considerations

All applicable international, national, and institutional guidelines for the care and use of animals were followed. The present

study was purely observational and, as such, no physical contact with the animal was made.

### Results

#### Observations from 6 to 27 December 2014

Between 6 and 27 December 2014, the lemon shark was sighted five times at the feeding site with a foreign object protruding out from its right side, ~10–15 cm anterior to the right pectoral fin (Table 1, Fig. 1a, b, and Video S1, available as Supplementary material to this paper). At this time it was not clear what the object was, only that it was of metallic composition. On 27 December 2014, a slight bulge was noticed on the ventral left side of the shark.

#### Observation on 2 January 2016

The affected lemon shark returned to the feeding ground and we observed the metallic object protruding further out of its right side (Video S1). At this time, we identified the object as a stainless steel 'fish stringer', a piece of equipment spear fishermen use to retain captured fish while continuing to hunt



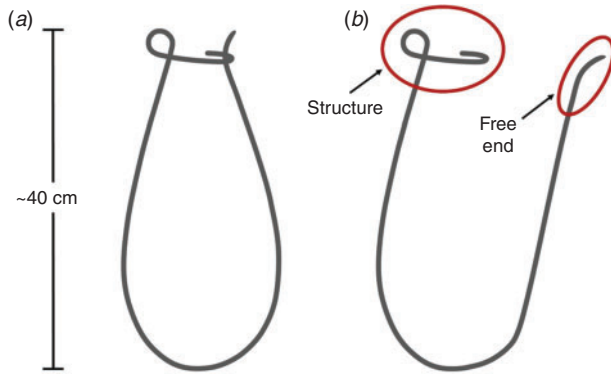
**Fig. 1.** Initial observations showing a metallic foreign object protruding from the right side of the lemon shark: (a) profile view of right side on 6 December 2014; (b) ventral view on 21 December 2014 shows no protrusion from the underside at this time. Inset, close-up image of the protrusion. (Photographs taken by Joanne Fraser.)

**Table 1.** Dates on which the individual was observed and the status of foreign object across the entire period

Visual references refer to the images and video footage (available as Supplementary material) associated with each observation. N/A, not available

Date	Status of object	Visual reference
6 December 2014	Protruding from right side only	Fig. 1a
13 December 2014	Protruding from right side only	N/A
21 December 2014	Protruding from right side only	Fig. 1b
22 December 2014	Protruding from right side only	N/A
27 December 2014	Protruding from right side only, ventral left side bulge first noticed	Video S1
10 January 2015	Protruding from right side only	Video S1
25 January 2015	Protruding from right side only	Video S1
2 January 2016	Protruding from both right and ventral side	Video S1
6 February 2016	Protruding from both right and ventral side	Fig. 2a, b
13 February 2016	Protruding from right and ventral side, ventral left side bulge prominent	Fig. 2c, d
14 February 2016	Protruding from right and ventral side, ventral left side bulge prominent	N/A
14 December 2016	Absent and wounds healed with visible scar tissue	Fig. 3a, b, Video S1

(Fig. 2). By this point, the free end of the open stringer (see Fig. 2b) had also breached the body wall and was protruding from the ventral surface of the shark.




**Fig. 2.** Schematic of (a) a closed stringer and (b) an open stringer seen protruding from a lemon shark (*Negaprion brevirostris*) at a dive site off Juno Beach (FL, USA). Ellipses highlight the section of the structure that was protruding from the right side of the shark, and the free end that was protruding from the ventral surface.

#### Observations from 6 to 14 February 2016


Between 6 and 14 February 2016, the affected lemon shark was sighted three times at the feeding site (Table 1). The fish stringer was protruding further from both the right and ventral sides. The individual appeared progressively more emaciated over the course of our observations to this point. The bulge on the ventral left side of the shark became much more prominent, probably caused by an item blocked by the stringer pushing against the coelom wall (Fig. 3c, d). At this time, we saw that the complex structure of the stringer was completely protruding from the right side of the shark (Fig. 3b), leaving only the curved, but otherwise smooth, shaft of the stringer inside the body cavity (Fig. 2b).

#### Observation on 14 December 2016

On 14 December 2016, the shark returned to the feeding site with the stringer fully ejected from its body cavity (Fig. 4a, b, and Video S1). We identified the individual by the scar tissue that was evident at both past protrusion sites, in addition to its size, sex and specific pectoral fin notching. The wounds were both closed and covered by scar tissue. At this time, based on our estimates of girth, the individual looked robust and in improved condition.



**Fig. 3.** Subsequent observations on (a, b) 6 and (c, d) 13 February 2016 showing the secondary protrusion on the ventral side of the lemon shark. (a, b) Orientation of the foreign object from the right (a) and from the ventral side (b); inset, the structure of the section protruding from the right side. (c, d) The ventral bulge that became more prominent on the left hand side of the shark, near the ventral protrusion, (c) from the right side and (d) from the left side. (Photographs taken by Joanne Fraser.)



**Fig. 4.** Final observations on 14 December 2016 showing the foreign body to be completely expelled from the lemon shark and the protrusion wounds healed. (a) Profile view of the right hand side; (b) ventral view. Insets show close-up images of the scar tissue. (Photographs taken by Joanne Fraser.)

## Discussion

We can only speculate on the events that resulted in the ingestion of the fish stringer by the lemon shark. The most probable scenario is that fish were being retained on the stringer and the lemon shark consumed them, resulting in the inadvertent ingestion of the stringer as well. We believe ingestion to be the only reasonable pathway into the body cavity. Fish stringers are merely a tool for the retention of captured fish, and are not a projectile used in spear fishing. We do not believe it is feasible that a diver would have been able to force such a large rigid object through the body wall of a free-swimming shark by hand. Such an unlikely scenario would have resulted in considerable external marking, which was not present on this individual. We can equally only speculate on the specific event that led to the final removal of the object. Given the shape and structure of the stringer, it most probably exited through the opening on the right side of the shark. It is difficult to ascertain how the object was finally expelled, but we postulate that the stringer was either snagged on a bottom structure or removed by a diver. Whatever the circumstances that led to the ingestion and expulsion of the stringer, this individual was able to expel the large foreign object over a minimum period of 435 days. This demonstrates a high level resilience and recovery after major internal trauma. Importantly, this lemon shark was able to survive for over 1 year under perforation of its stomach lining, coelom and muscle wall.

Carcharhinid sharks are well documented to survive and exhibit considerable tissue regeneration following extensive external trauma (Bird 1978); however, we observed that they are also resilient to considerable internal damage. Our observations have implications in relation to other internal injuries experienced by sharks, such as gut (or deep) hooking. Commonly, estimates of fisheries-related mortality for sharks include gut hooking as a factor in post-release survival estimates (e.g. Campana *et al.* 2006). Our account suggests that sharks may be particularly resilient to such internal injuries, including perforation of the stomach wall. This may be expected because the prey items of many shark species include porcupine fish, spiny crustaceans and stingrays (Gudger 1949; Strong *et al.* 1990; Chapman and Gruber 2002). All such prey items have the

potential to cause internal damage after consumption. We suggest that the ability to sustain and recover from such internal trauma would confer a strong fitness factor, and would be evolutionarily beneficial for sharks to survive and reproduce in the face of such injury. Equally, our observations lend credence to the practice of cutting leaders on gut-hooked sharks rather than trying to remove the hook, as demonstrated for other fish species to result in higher survival rates (Fobert *et al.* 2009; Weltersbach *et al.* 2016). The present observations suggest that lemon sharks, and most probably other shark species, are able to expel large objects such that their ingestion is not necessarily fatal.

## Conflicts of interest

The authors declare that they have no conflicts of interest.

## Supplementary material

The supplementary material for this paper is in the form of a video file (see <https://youtu.be/z6ZybPWn0sc>).

## Acknowledgements

The authors acknowledge Captain Luis A. Roman of Calypso Dive Charters (Lake Park, FL, USA) for providing continued vessel support throughout these observations. The authors also acknowledge the editor and two anonymous reviewers for their constructive comments on the earlier draft of this manuscript, which improved the current version.

## References

- Bird, P. M. (1978). Tissue regeneration in three carcharhinid sharks encircled by embedded straps. *Copeia* **1978**(2), 345–349. doi:10.2307/1443580
- Brunnschweiler, J. M., Andrews, P. L., Southall, E. J., Pickering, M., and Sims, D. W. (2005). Rapid voluntary stomach eversion in a free-living shark. *Journal of the Marine Biological Association of the United Kingdom* **85**(05), 1141–1144. doi:10.1017/S0025315405012208
- Campana, S. E., Marks, L., Joyce, W., and Kohler, N. E. (2006). Effects of recreational and commercial fishing on blue sharks (*Prionace glauca*) in Atlantic Canada, with inferences on the North Atlantic population.

- Canadian Journal of Fisheries and Aquatic Sciences* **63**(3), 670–682. doi:10.1139/F05-251
- Castles, A. C. (1995). 'The Shark Arm Murders: the Thrilling True Story of a Tiger Shark and a Tattooed Arm.' (Wakefield Press: Adelaide, SA, Australia.)
- Chapman, D. D., and Gruber, S. H. (2002). A further observation of the prey-handling behavior of the great hammerhead shark, *Sphyrna mokarran*: predation upon the spotted eagle ray, *Aetobatus narinari*. *Bulletin of Marine Science* **70**(3), 947–952.
- Christie, B. L. (2012). Intestinal eversion in the Atlantic sharpnose shark, *Rhizoprionodon terraenovae*, a behavior ubiquitous among elasmobranch fishes? *Gulf of Mexico Science* **30**(1), 50–53.
- Fobert, E., Meining, P., Colotelo, A., O'Connor, C., and Cooke, S. J. (2009). Cut the line or remove the hook? An evaluation of sublethal and lethal endpoints for deeply hooked bluegill. *Fisheries Research* **99**(1), 38–46. doi:10.1016/J.FISHRES.2009.04.006
- Gapps, S. (2011). A strange history of shark stomachs. *Signals* **93**, 4–13.
- Gudger, E. W. (1949). Natural history notes on tiger sharks, *Galeocerdo tigrinus*, caught at Key West, Florida, with emphasis on food and feeding habits. *Copeia* **1949**(1), 39–47. doi:10.2307/1437661
- Haetrakul, T., Munanansup, S., Assawawongkasem, N., and Chansue, N. (2009). A case report: stomach foreign object in whaleshark (*Rhincodon typus*) stranded in Thailand. In 'Proceedings of the 4th International Symposium on SEASTAR2000 and Asian Bio-logging Science (the 8th SEASTAR2000 Workshop)', 15–17 December 2007, Phuket, Thailand. pp. 83–85. Available at [https://repository.kulib.kyoto-u.ac.jp/dspace/bitstream/2433/71015/1/8thSEASTAR\\_83.pdf](https://repository.kulib.kyoto-u.ac.jp/dspace/bitstream/2433/71015/1/8thSEASTAR_83.pdf) [Verified 30 May 2017]
- Kessel, S. T., Chapman, D. D., Franks, B. R., Gedamke, T., Gruber, S. H., Newman, J. M., White, E. R., and Perkins, R. G. (2014). Predictable temperature-regulated residency, movement and migration in a large, highly mobile marine predator (*Negaprion brevirostris*). *Marine Ecology Progress Series* **514**, 175–190. doi:10.3354/MEPS10966
- Lloyd, R., and Lloyd, C. (2011). Surgical removal of a gastric foreign body in a sand tiger shark, *Carcharias taurus* Rafinesque. *Journal of Fish Diseases* **34**(12), 951–953. doi:10.1111/J.1365-2761.2011.01313.X
- Strong, W. R., Snelson, F. F., and Gruber, S. H. (1990). Hammerhead shark predation on stingrays: an observation of prey handling by *Sphyrna mokarran*. *Copeia* **1990**(3), 836–840. doi:10.2307/1446449
- Weltersbach, M. S., Ferter, K., Sambahaus, F., and Strehlow, H. V. (2016). Hook shedding and post-release fate of deep-hooked European eel. *Biological Conservation* **199**, 16–24. doi:10.1016/J.BIOCON.2016.04.015
- Wiersma, G., Verhoog, P., Fowler, S., and Meekan, M. (2016). The first field observation of intestinal eversion by a shark. *Marine Biodiversity* **46**(1), 17–18. doi:10.1007/S12526-015-0341-9